

Erectile Restoration

Penile Prosthesis Surgery

Post-operative Considerations

- Penile Prosthesis Infection
- Correction of Impending Cylinder Erosion
- Repairing Weakened Tunica
- Correction of the SST Deformity (Hypermobile Glans)
- Prostate Cancer, Radiation and the Penile Implant

Post-operative Considerations

Penile Prosthesis Infection

♂ Recent work shows that virtually all implant infections come from bacterial contamination at the time of surgery. Blood borne infections, e.g. after dental work, are a distinct rarity. In most operations the antibiotics given to the patient and the body's defense mechanisms are enough to prevent the bacteria contaminating the implant during surgery from creating a clinical infection.

♂ In the past, approximately 4% of penile implant operations in patients without risk factors became clinically infected. Risk factors increased the incidence of infection. Many so-called risk factors have been studied but only a few actually increased the incidence of infections compared to the patient without the risk factor.

Post-operative Considerations

Penile Prosthesis Infection

Conditions Thought To Increase Implant Infection Risk But Never Proven

1. Coincident Circumcision
2. Radiation Therapy
3. Incision Location (infrapubic vs. scrotal)
4. Obesity
5. Transplant Patients on Immunosuppression
6. HIV or Hepatitis Patients
7. Diabetics with poor control of blood sugar

Post-operative Considerations

Penile Prosthesis Infection

Conditions Proven to Increase Risk of Infection in implants

1. Spinal Cord Injury 9%
2. Diabetes Mellitus 8%
3. Revision Surgery 10%
4. Patients on Prednisone 20%

Post-operative Considerations

Penile Prosthesis Infection

There have been several recent studies published that give us much new knowledge about bacterial colonization of implants and how the colonization of the implants affects patients and their chance of subsequent infection. Bacteria contaminate all implant operations at the time the wound is open.

The bacteria come from the surgeon, his team and from the patient. Obviously, the longer the wound is open the more bacteria drift into the tissues. Most of the bacterial contamination is from skin organisms like Staph. epidermidis or Staph. lugdunensis. Occasionally (< 25%), more serious bacteria can contaminate from the GI tract, GU or respiratory tract - E. coli, Enterococcus, yeast, Pseudomonas and others.

In most instances, the body's defense mechanisms, the preoperative antibiotics or antibiotics eluted off the implant will contain the bacteria. There are some practical steps that can be done in the operating room to keep the inoculums low so bacterial containment is more likely.

Post-operative Considerations

Penile Prosthesis Infection

Salvage Strategy When Patient Has Clinical Infection: Seventy five percent of patients who present with a clinical infection are infected with skin organisms from contamination at the time of surgery. The other 25% are infected with more toxic bacteria from the GI, GU or respiratory tracts, also imported at the time of surgery.

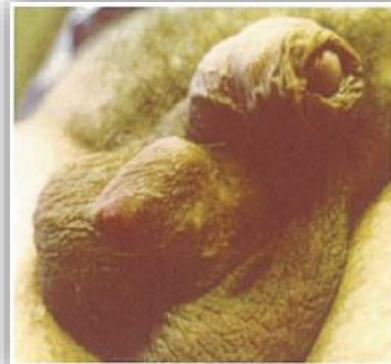It is important to understand that the odds of preserving the patient 's implanted status with a salvage operation are much higher if they are infected with skin organisms rather than the toxic organisms.

Post-operative Considerations

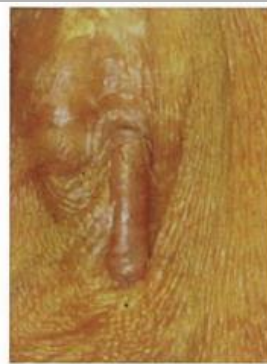Penile Prosthesis Infection

Signs and Symptoms of Patient Infected with Skin Bacteria

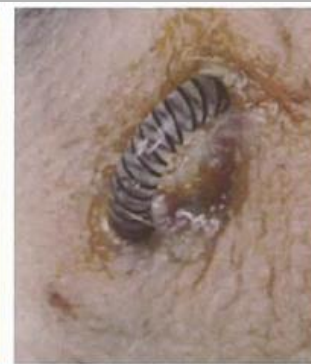1. Implant pain beyond 6 weeks
2. Pump stuck to the skin
3. Mass surrounding the pump
4. Sinus tract draining clear material
5. Wound separation and tubing visible
6. Over six weeks since the implant surgery before symptoms present



Pump stuck to skin



Tubing stuck to skin



Tubing erosion



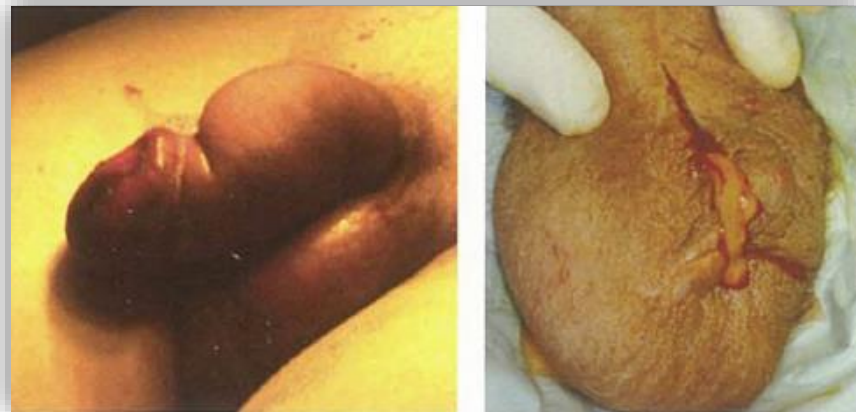Sinus tract from components

Post-operative Considerations

Penile Prosthesis Infection

Signs and Symptoms of Patient Infected with More Toxic Bacteria

1. Scrotal swelling, redness
2. Sick Patient with fever, elevated white blood cell count and severe discomfort
3. Exposed component
4. Gross pus rather than clear drainage
5. Less than six weeks since the implant surgery



Pseudomonas 10 days post op

E.Coli 2 weeks post op

Post-operative Considerations

Penile Prosthesis Infection

Patients with skin organism implant infection have a much better chance of salvage surgery success than patients infected with toxic bacteria. Fortunately, skin organism infections are three times more common than infection with the bad bugs. Skin bacteria are weak and do not penetrate tissue and permeate areas of the body outside the implant spaces. Toxic bacteria are powerful and can penetrate tissue deeply, infect the blood and wreck havoc with patients. Salvage is successful with skin organisms because they are weak and only live in the implant spaces and on the components.

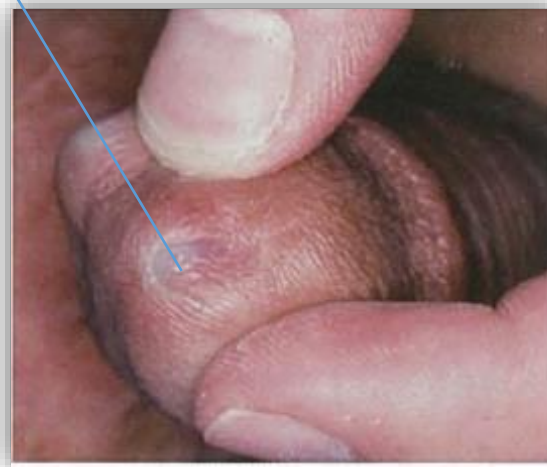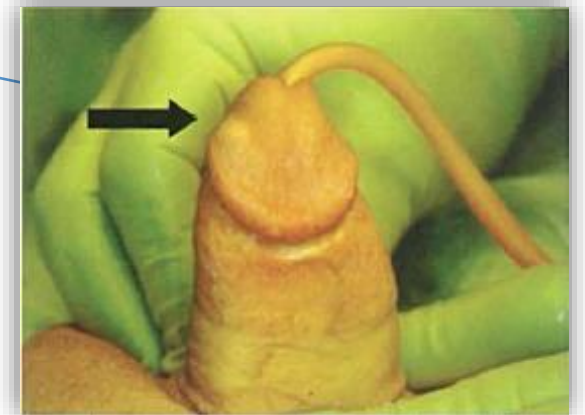
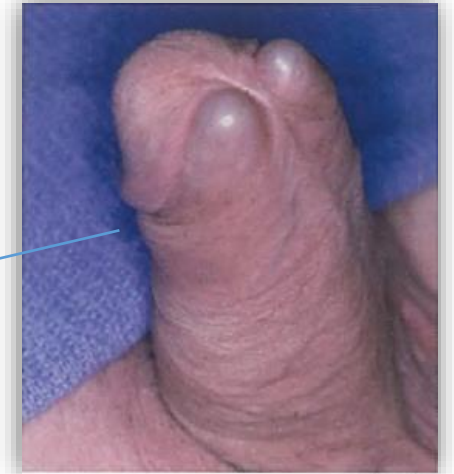The most important factor to help determine whether salvage should be attempted, **how long has it been since the original surgery? If it is less than 6 weeks the occasional implanter is advised to remove the implant. If it is more than 6 weeks the physician will have a 92% chance of success with salvage.**

Post-operative Complications and Their Solutions

Correction of Impending Cylinder Erosion

Impending cylinder erosion occurs when the cylinder has worked its way through the tough tunica albuginea and is pressing

- Under the skin in the distal penis
- Into the glans penis
- Impinging upon the urethra at the meatus

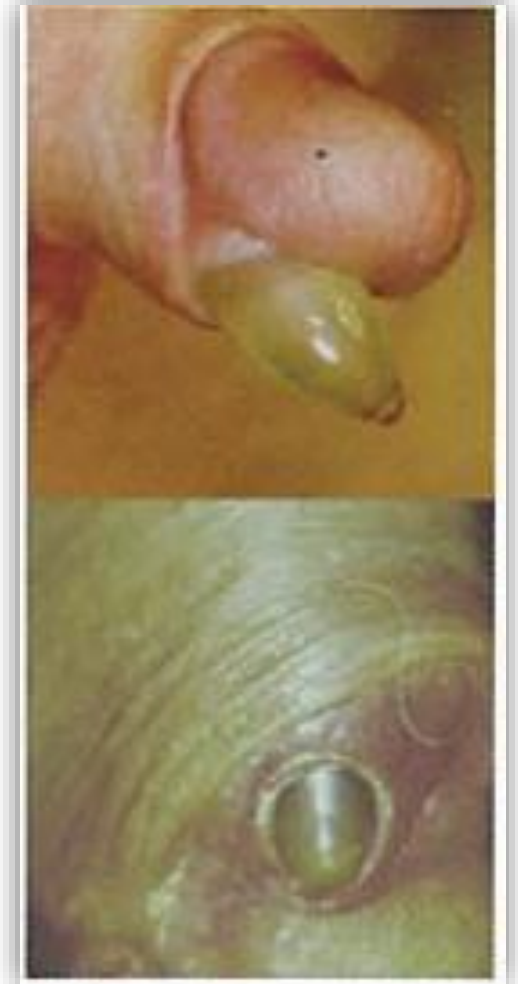

Post-operative Complications and Their Solutions

Correction of Impending Cylinder Erosion

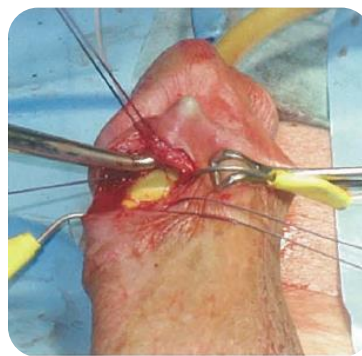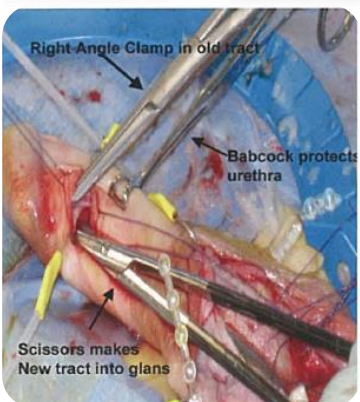
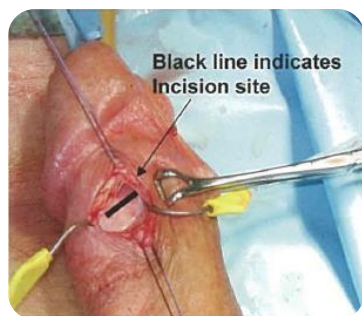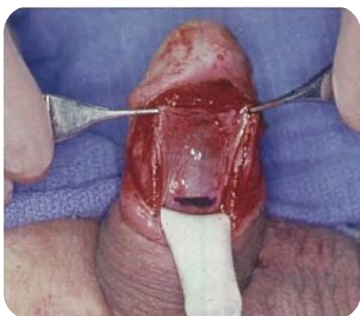It is imperative to address impending cylinder erosion since if left unchecked, it is inevitable the cylinder will erode through the tissue; the implant will become exposed and by definition, infected. The physician must be careful to distinguish impending cylinder erosion of a benign nature from a cylinder that is eroding because of an underlying infection. This is easy to do since an infected implant will have signs of infection such as redness, induration and perhaps slight drainage.

Impending cylinder erosion without infection is usually the result of vigorous dilatation with small sharp dilators during the implantation . The tunica was punctured and it was not evident at the time of implantation. Over the succeeding few months or years, with usage, the cylinders worked their way into the path of least resistance the tunical defect. The problem may also be caused by frequent, enthusiastic sexual activity.



Post-operative Complications and Their Solution

Correction of Impending Cylinder Erosion



The repair was originally described as making an incision in the distal penis. The capsule was incised and the cylinder deflated and cylinder tip removed from the capsular incision.

The back wall of the capsule was then incised with the electrocautery and the scissors and dilators utilized to make a new resting place for the distal tip of the cylinder beneath the two layers of capsule.

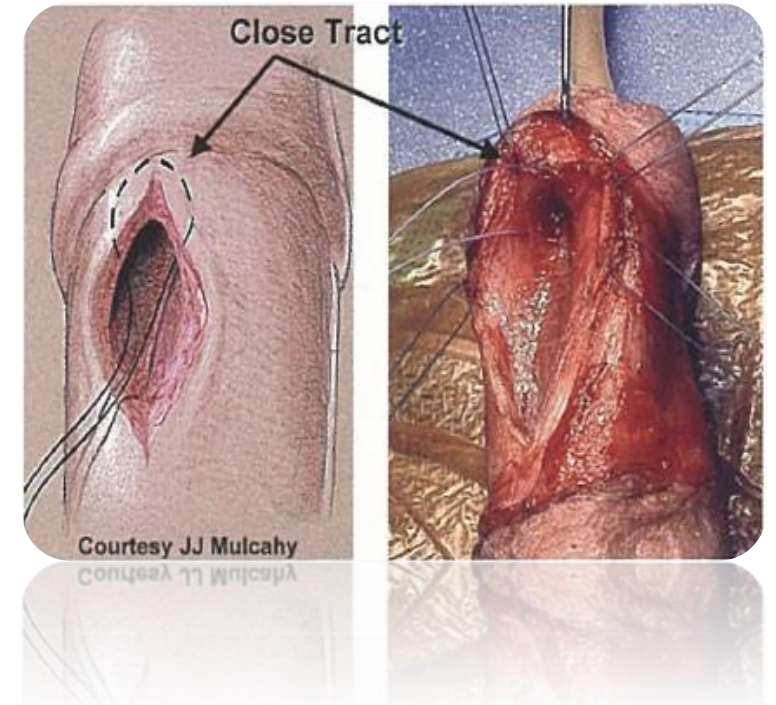
The cylinder tip is then passed into the new tract beneath the capsule and the Furlow Inserter fired.

If the same cylinder is utilized a new guide suture can be constructed by passing a 00 Vicryl through the groove in the tip of the cylinder. Obliteration of the old tract by incorporating it with the corporotomy then buttressed the cylinder tip from repeat erosion. In effect the new cylinder tip location had two layers of the tough capsule to prevent it from causing repeat mischief.


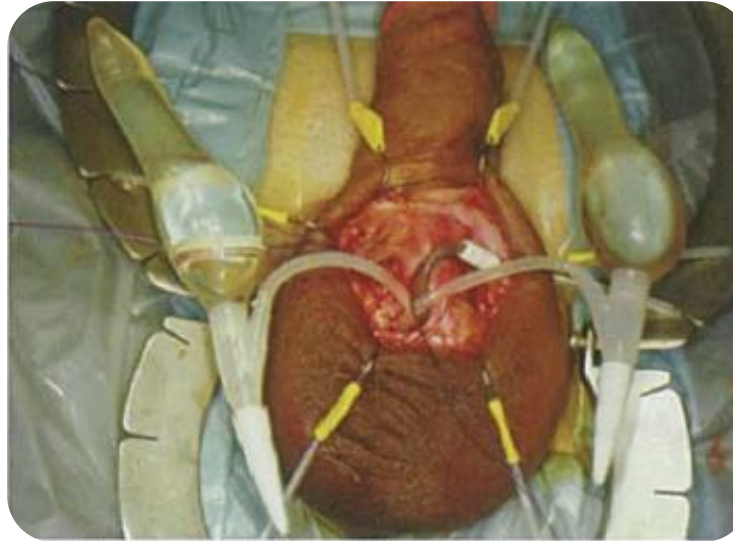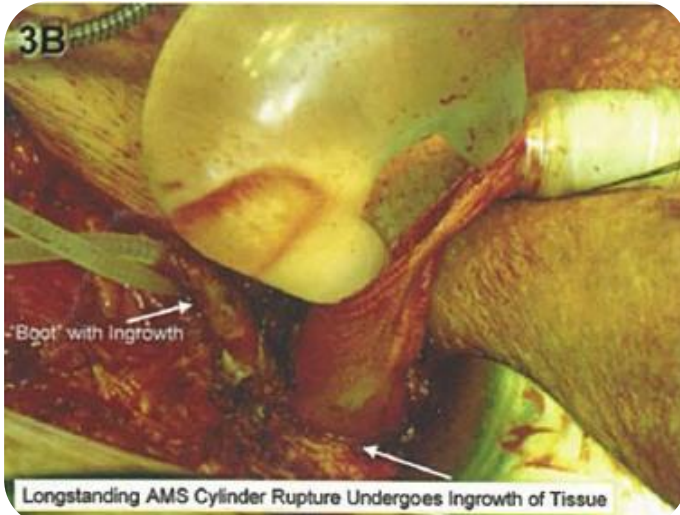
Post-operative Complications and Their Solutions

Correction of Impending Cylinder Erosion

If the cylinder is impinging on the glans or urethra, one additional step is necessary. The distal aberrant tract of the capsule is closed with a purse string of non-absorbable suture. Then the identical rerouting of the cylinder tip described in the preceding page is performed through the back wall of the interior wall of capsule.



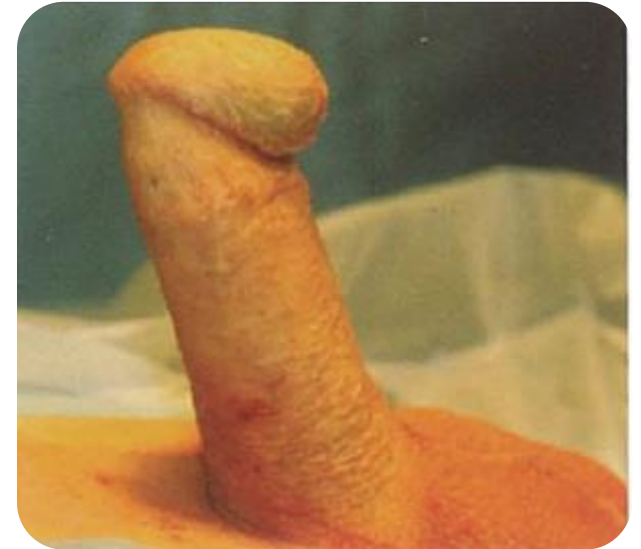Post-operative Complications



Post-operative Complications and Their Solutions

Correction of the SST Deformity (Hypermobile Glans)

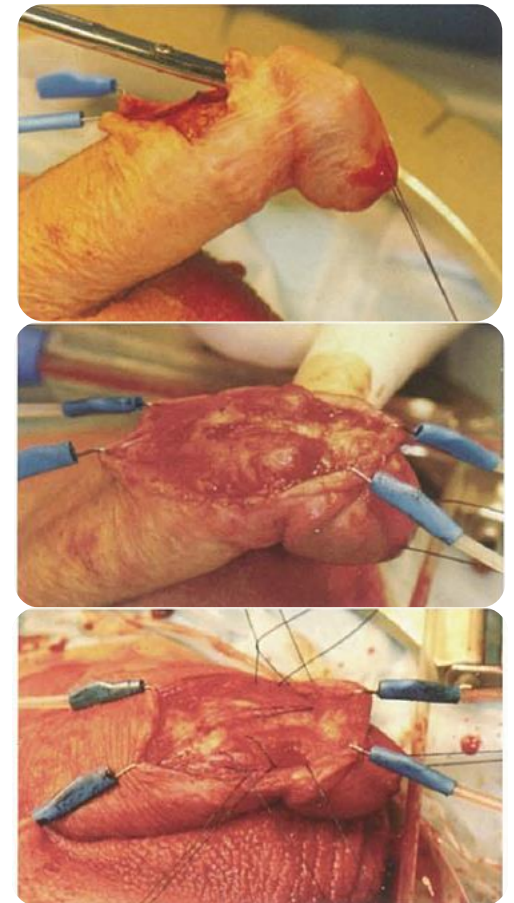
Hypermobility of the glans following prosthesis implantation is an unusual complication. It has been called glans bowing, the Concord deformity and SST - the latter two descriptions in reference to the super sonic transport airplane's nose. It may be seen when the implant is improperly sized (too short) due to inadequate distal dilatation or when a properly sized implant has acted as a tissue expander. Other cases may result from unrecognized proximal corporal perforation allowing migration of the cylinder into the perineum leaving the glans unsupported. Finally the SST deformity may result in cases of correct implantation for unknown reason. It is more commonly SST or Hypermobile Glans seen in uncircumcised patients. Occasionally, following a routine implantation, the glans appears too mobile. Despite encouragement in the literature to perform immediate glans fixation, our experience has been that the subsequent capsule formation around the cylinder tip often corrects the problem. If the glans still appears floppy after healing, it can be corrected easily as a subsequent procedure.



Post-operative Complications and Their Solutions

Correction of the SST Deformity (Hypermobile Glans)

A hemicircumcising incision is made proximal to the glans and dissection carried down to the tunica albuginea. The tunica is not opened but used as a guide for distal dissection underneath the glans on either side of the midline. In effect, the SST is increased by the creation of these spaces beneath the glans and the cylinder tips will be visualized in the distal corpora under the tunica. Deep non-absorbable sutures (00 Ethibon on a CT2 needle) from underneath into the glans are placed. The deflated cylinders are milked in their capsular sheaths proximally and the sutures are placed in the distal tunica over the cylinder tips without injuring the cylinder.

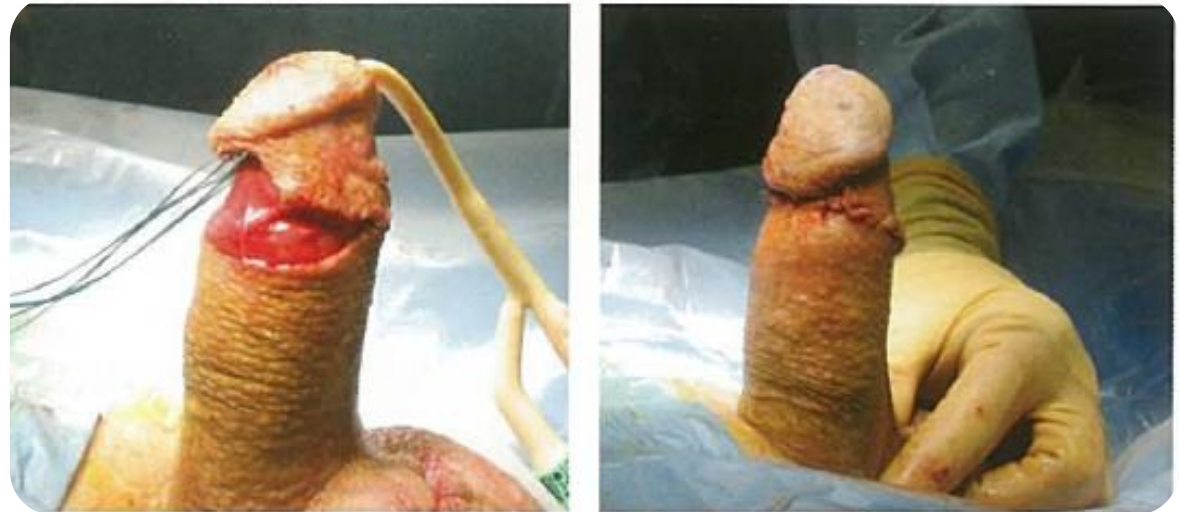

Post-operative Complications and Their Solutions

Correction of the SST Deformity (Hypermobile Glans)

Tying the sutures "hitches" the floppy glans to the distal tunica correcting the problem.

Dimples on the glans may be apparent from the underlying sutures (two on each side) but these recede with time.



Prostate Cancer, Radiation and the Penile Implant

1. Is it safe to perform an MRI on a patient with a penile implant?

Components of both the ZSI penile implants and the sphincter showed no unsafe magnetic interaction when subjected to magnetic field strengths up to 1.5 Tesla. The small stainless steel components of ZSI prostheses are nonferromagnetic and are only minimally attracted by the static magnet field. There may be some distortion of the magnetic field close to the implant but it is unlikely these components will interfere with normal magnetic resonance imaging.

2. Is it safe to perform radiation therapy on a patient with a penile implant?

The silicone elastomer that is used for construction of both the penile implants and urinary sphincter is highly resistant to radiation changes. Standard x-rays, CT imaging and high dose radiotherapy will not damage the implants.

3. The patient is post prostatectomy for prostate cancer and has an IPP; he needs XRT.

Radiation therapy can be safely given with no ill effects to the IPP.

Prostate Cancer, Radiation and the Penile Implant

4. The patient has an IPP and now needs a prostatectomy.

The only problem for this scenario is that the reservoir is lying over where the surgeon must traverse to remove the prostate. The solution is to open the capsule, remove the reservoir from the patient and store it (still connected) in an antibiotic soaked lap sponge. Then incise the wall of the capsule and proceed with the prostatectomy. A previously placed IPP in a patient scheduled for laparoscopic or Robotic prostatectomy may contraindicate these modalities and force the surgery to be performed in the traditional open manner.

5. Will the patient with both IPP and AUS set off a metal detector at the airport?

No, the amount of metal in these devices is minimal and insufficient to set off even the most sensitive detectors. This a reasonable patient question, however, since hip implant patients are consistently pulled out of line in this post 9/11 increased security atmosphere.

Thank you for your attention